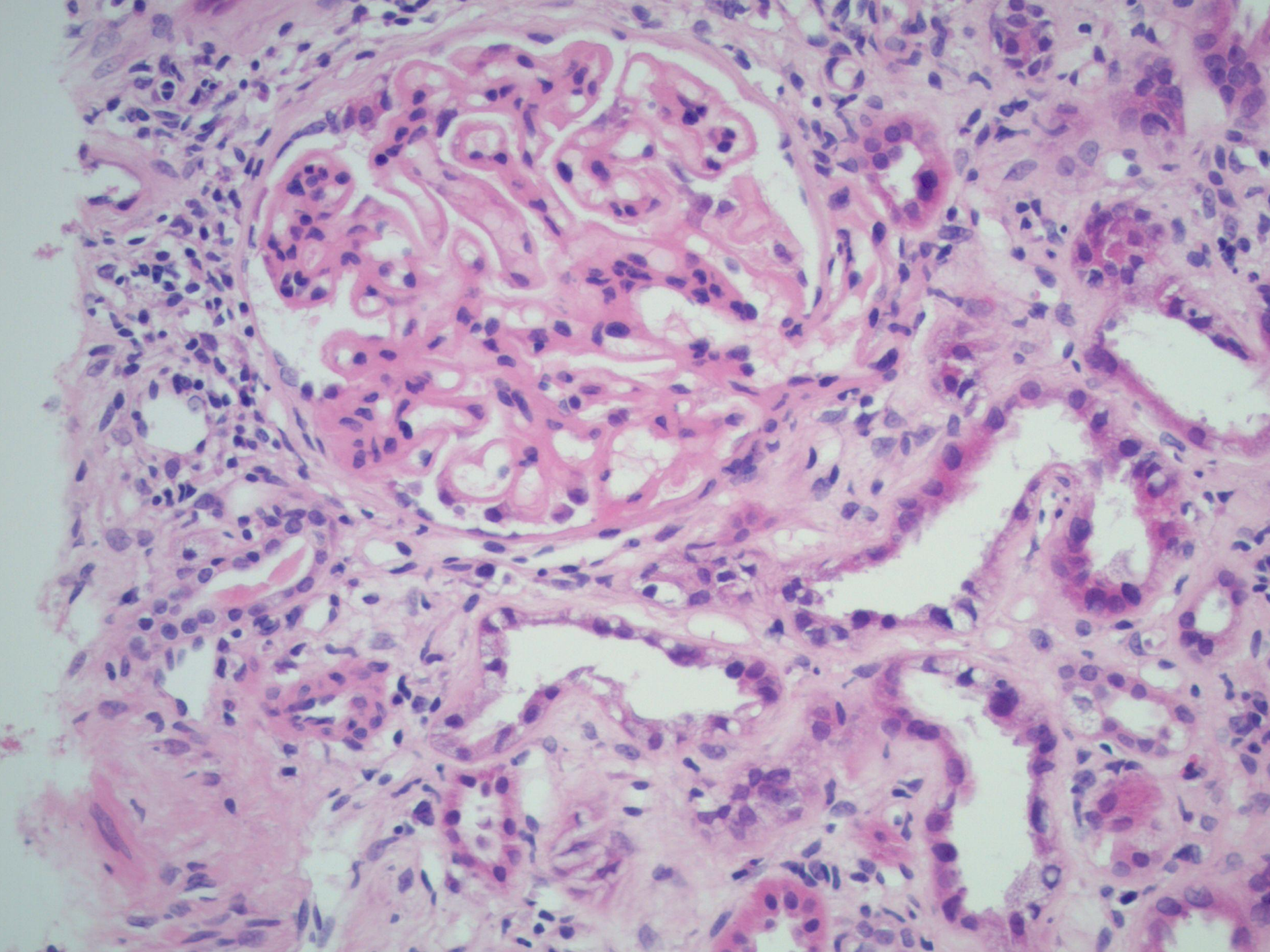
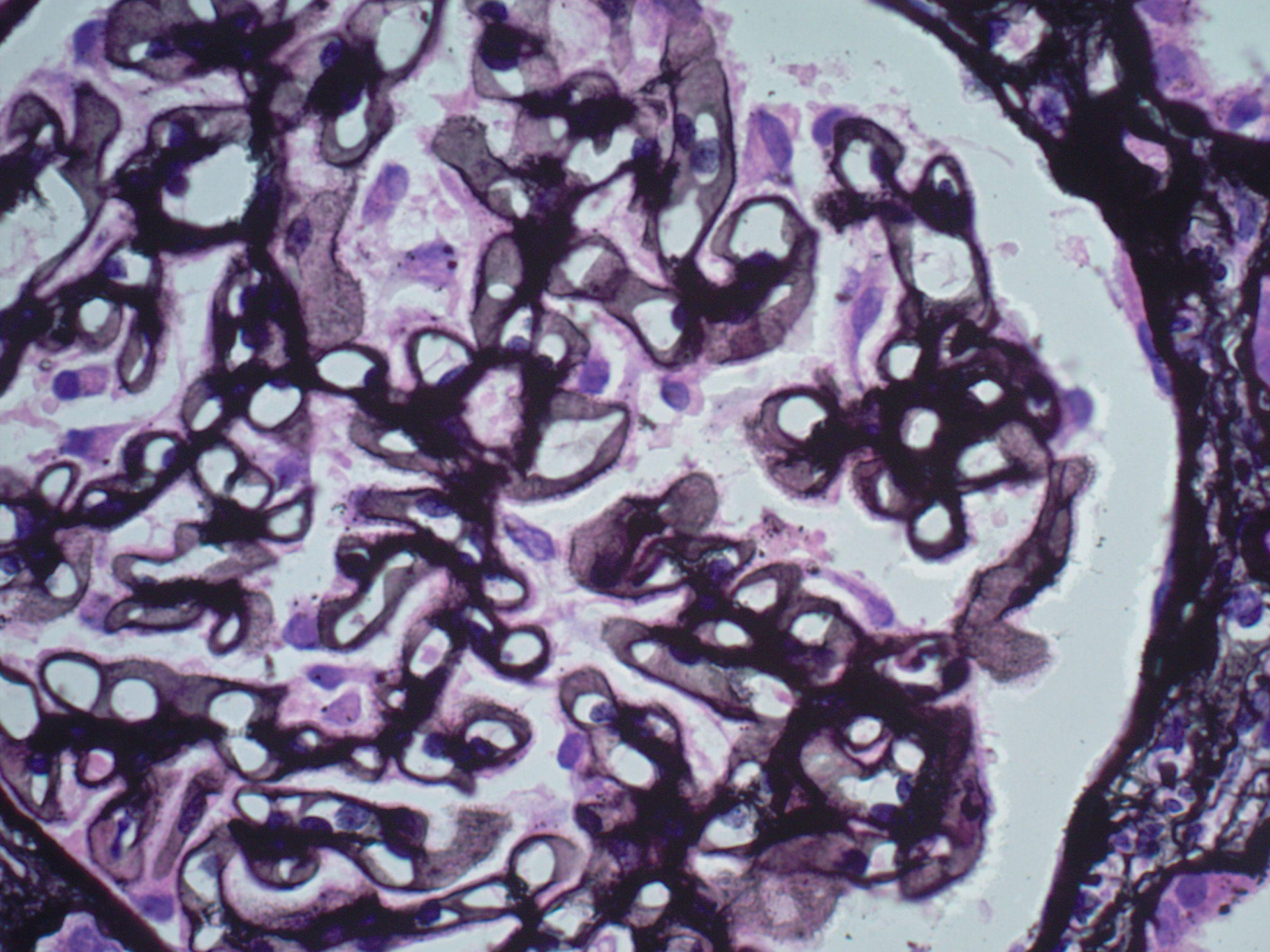


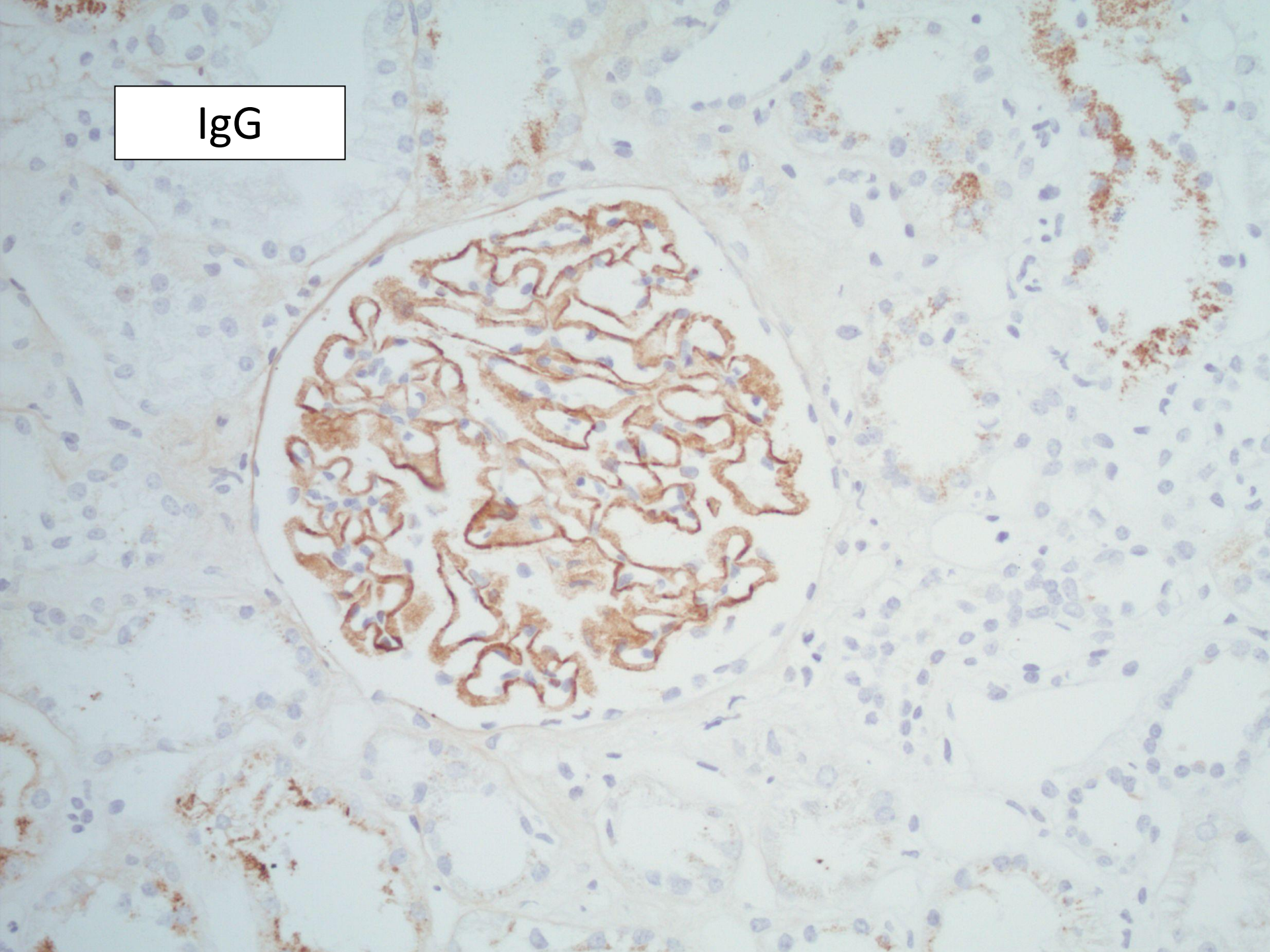
Case 3

- Male aged 35.
- Nephrotic syndrome.
- Previous biopsy 1 year ago reported as minimal change disease.
- Treated with cyclophosphamide and steroids.





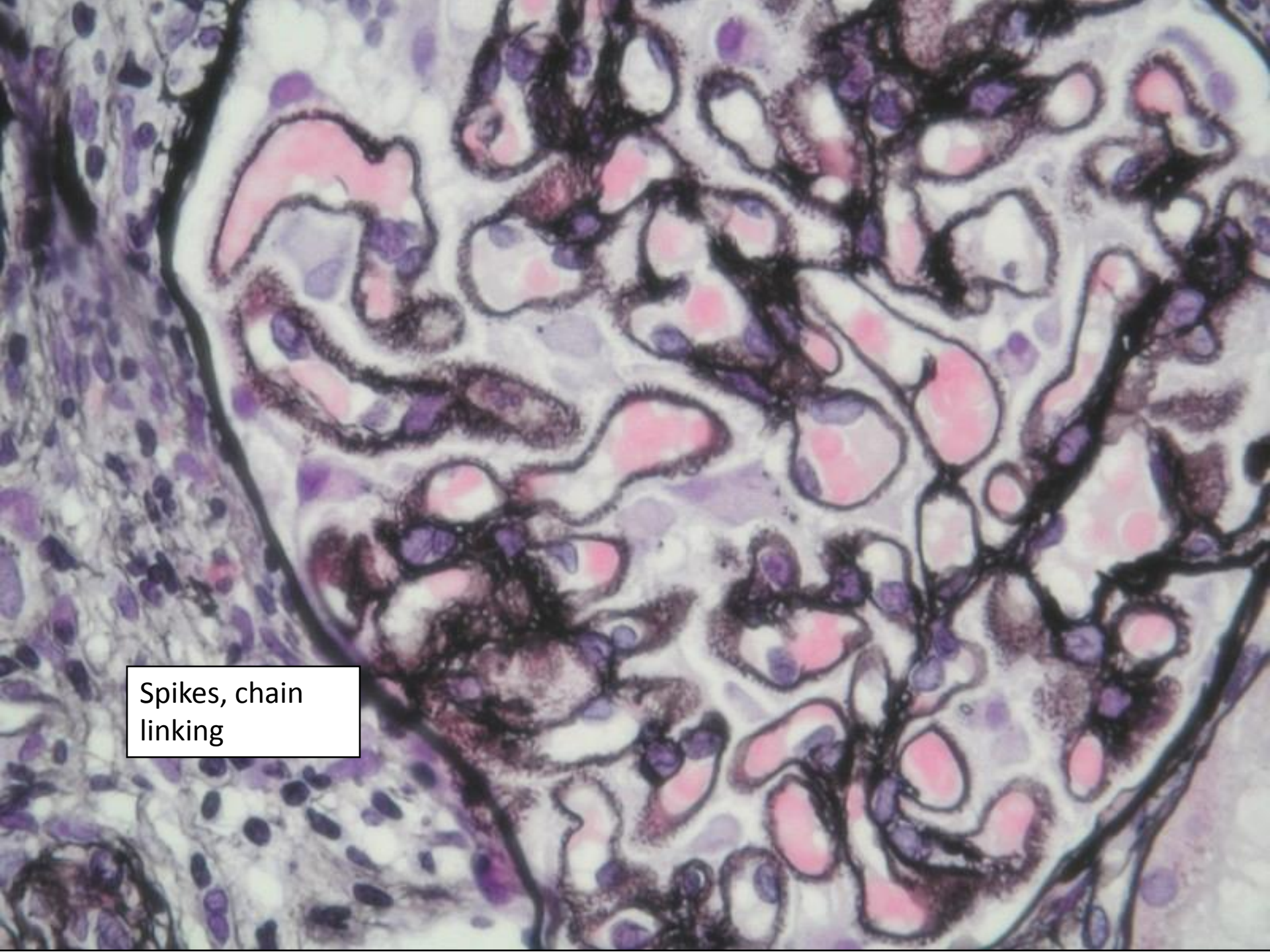
IgG



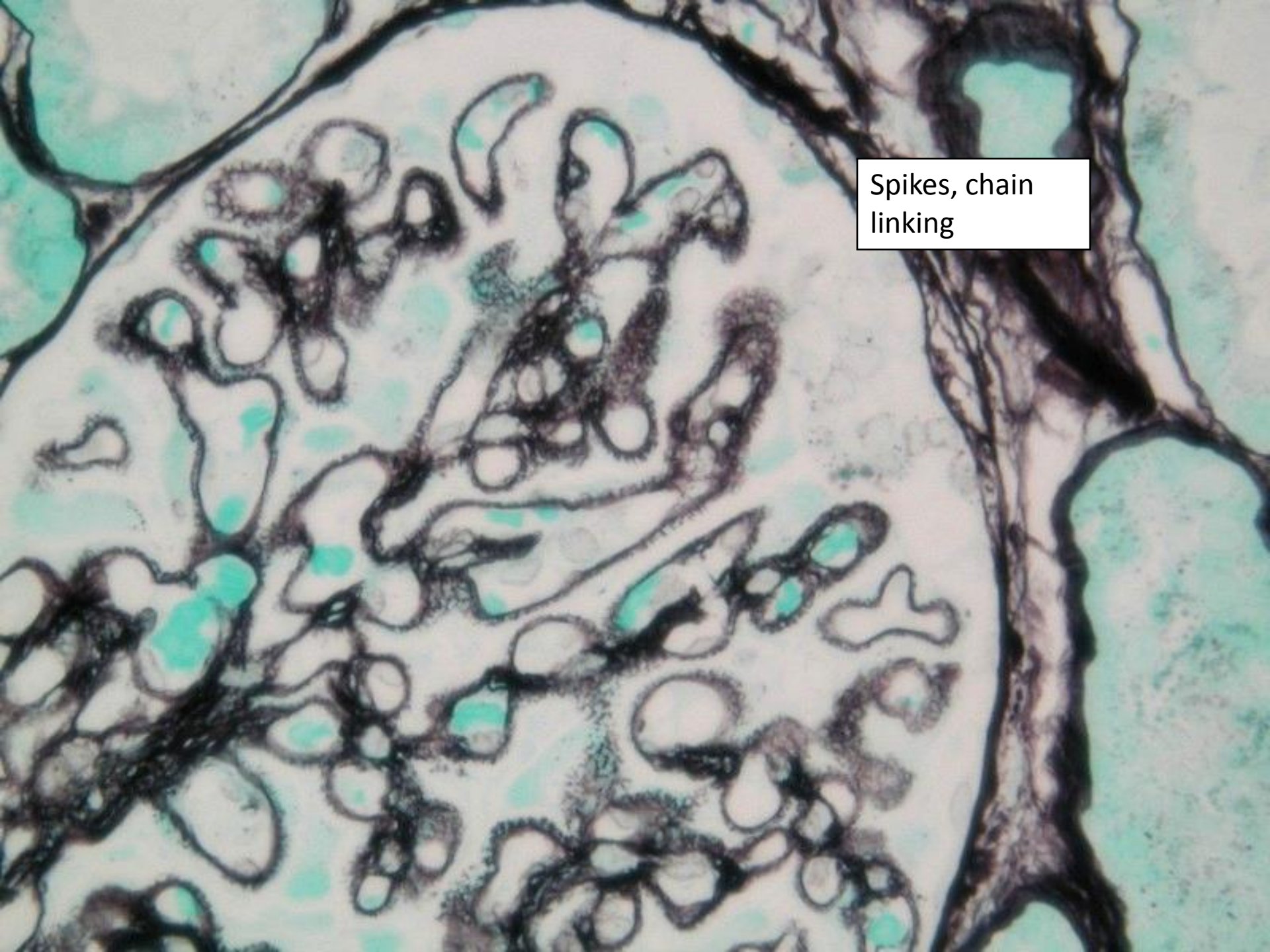
- What is the diagnosis?
- What other diagnoses are possible?
- What do you want to do to investigate further?

Membranous nephropathy

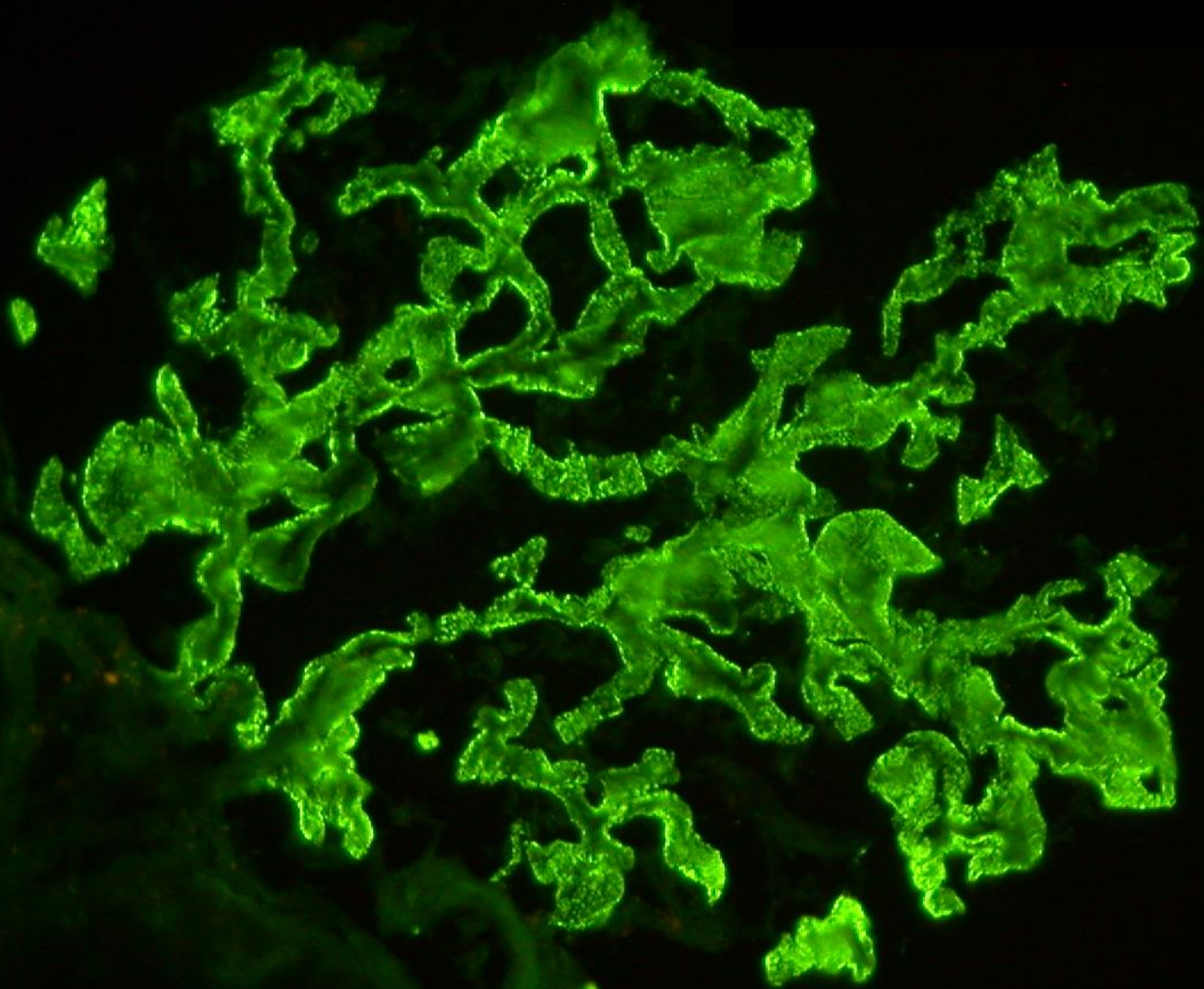
- classical appearance very distinctive
- spikes on silver stain
- IgG and C3 on immunohistochemistry
- sub-epithelial deposits on EM
- may be normal on light microscopy



Spikes, chain linking



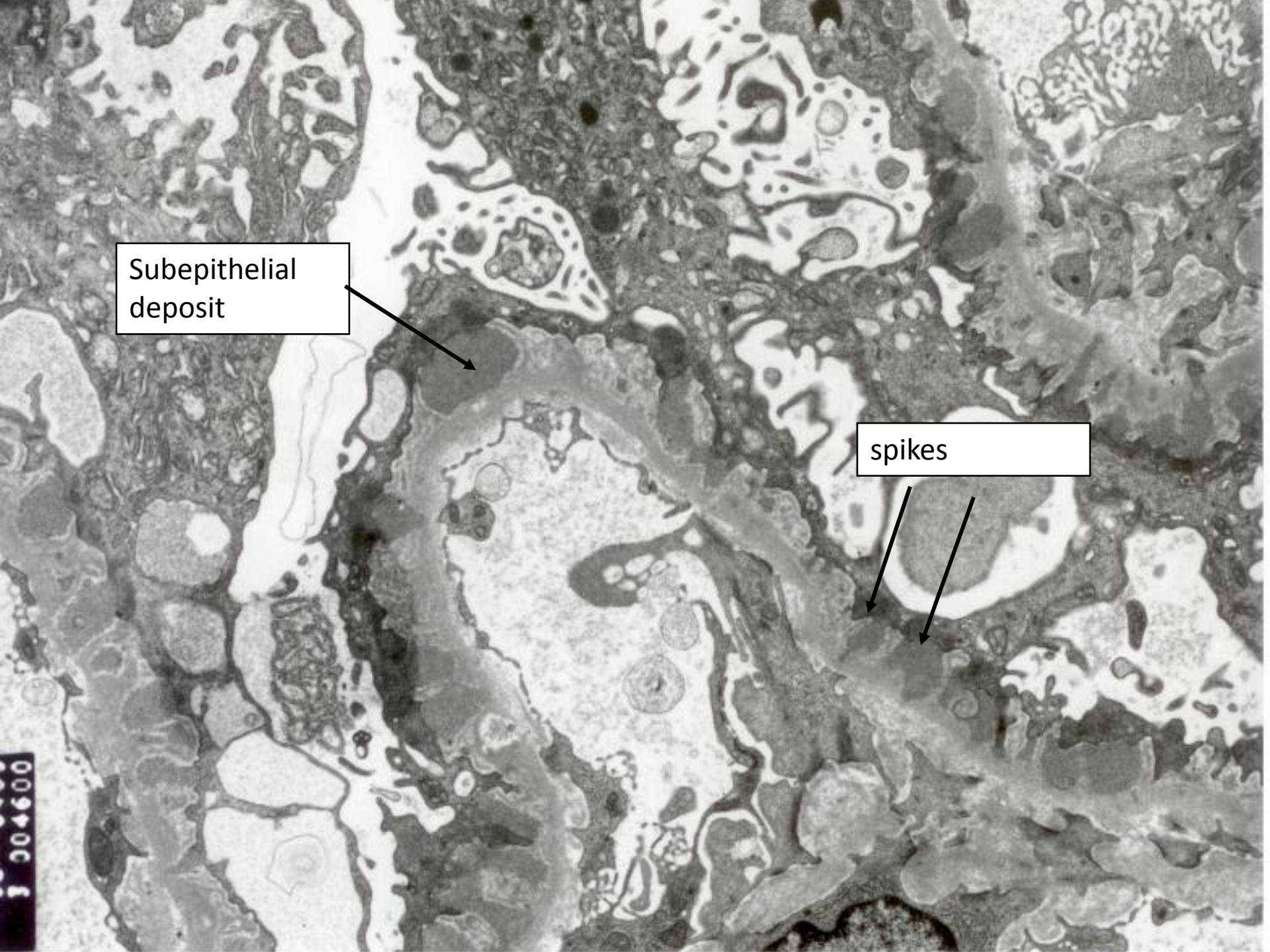
Spikes, chain linking

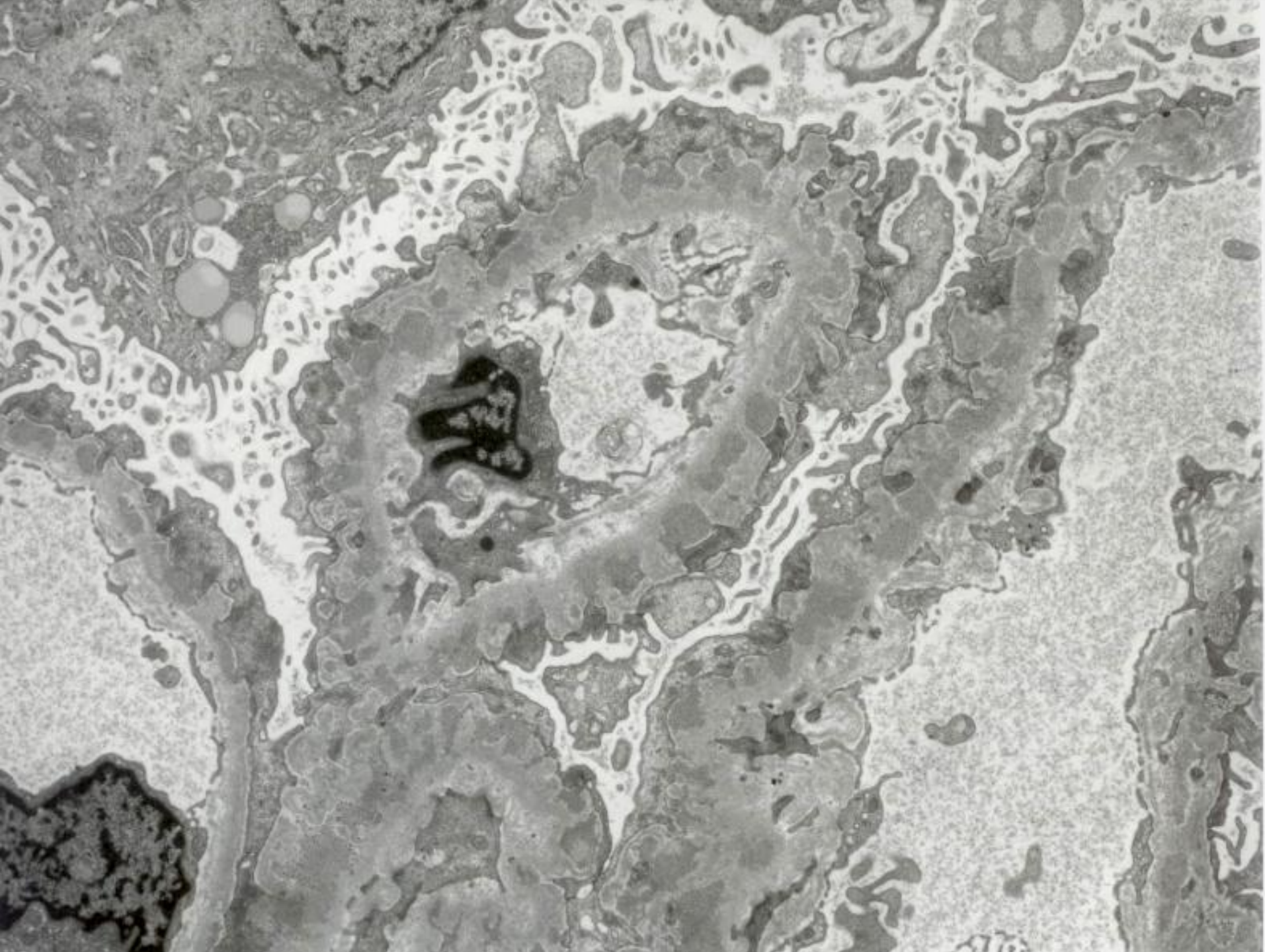


Subepithelial
deposit

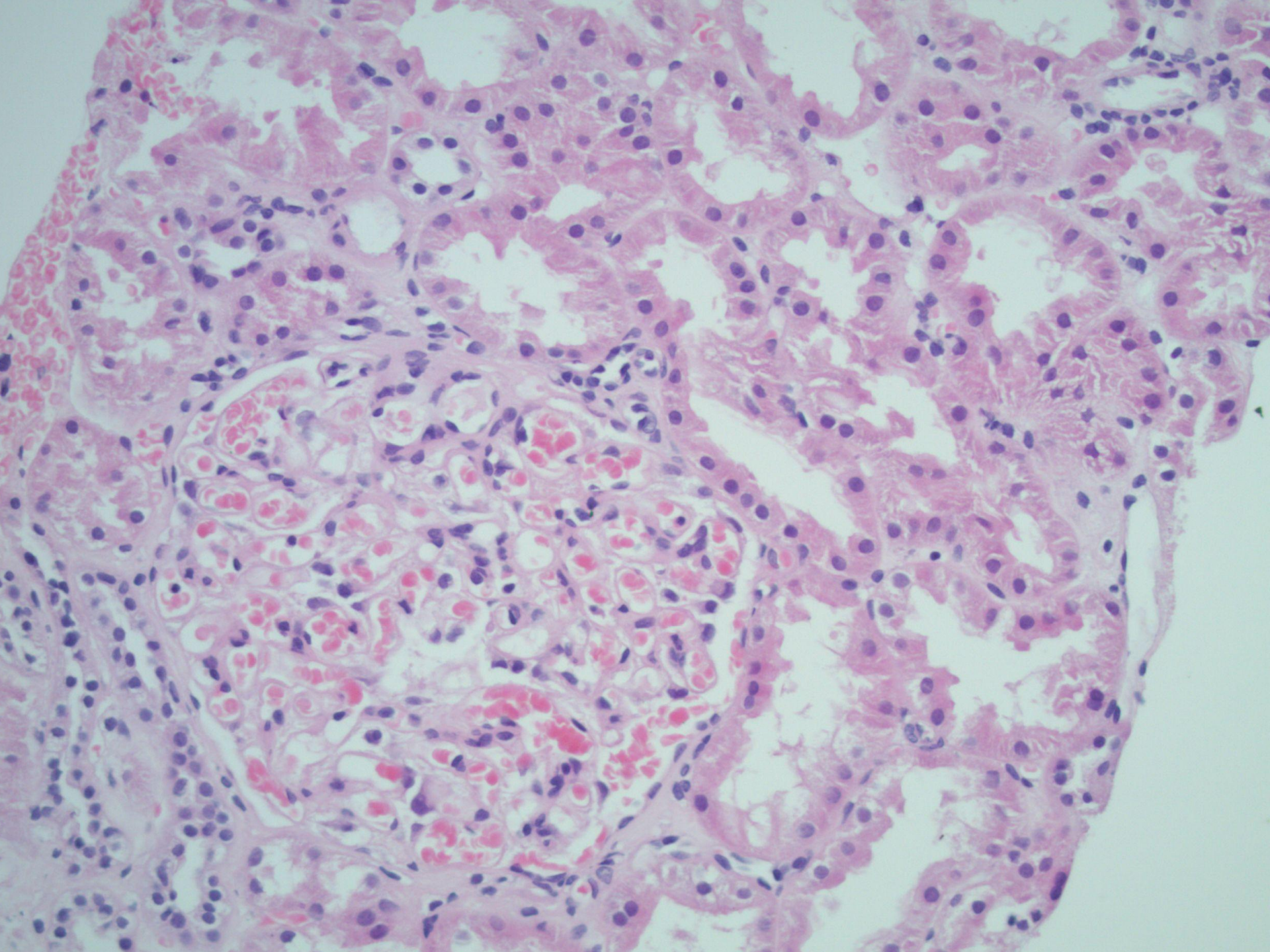
spikes

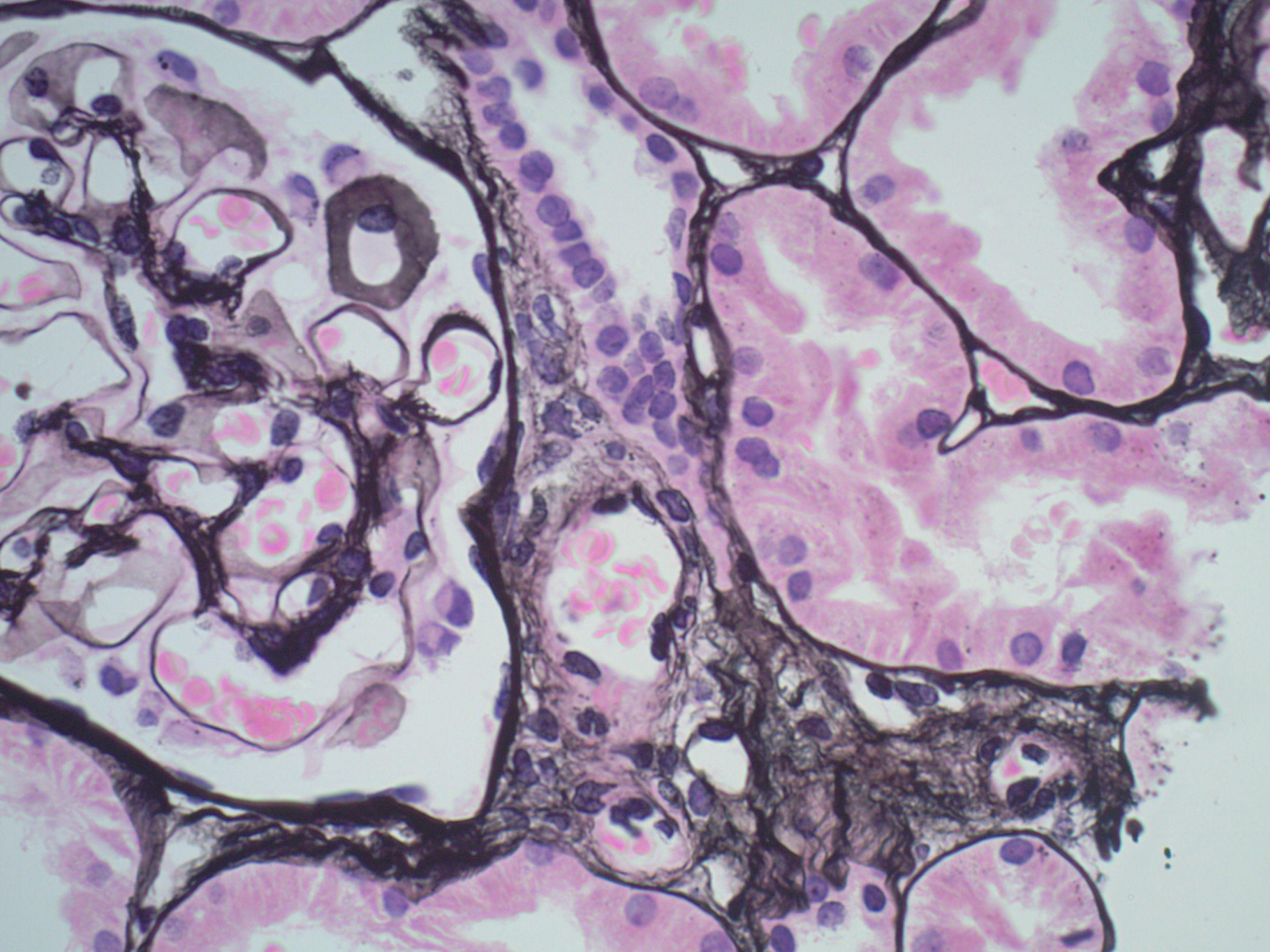
J 004600



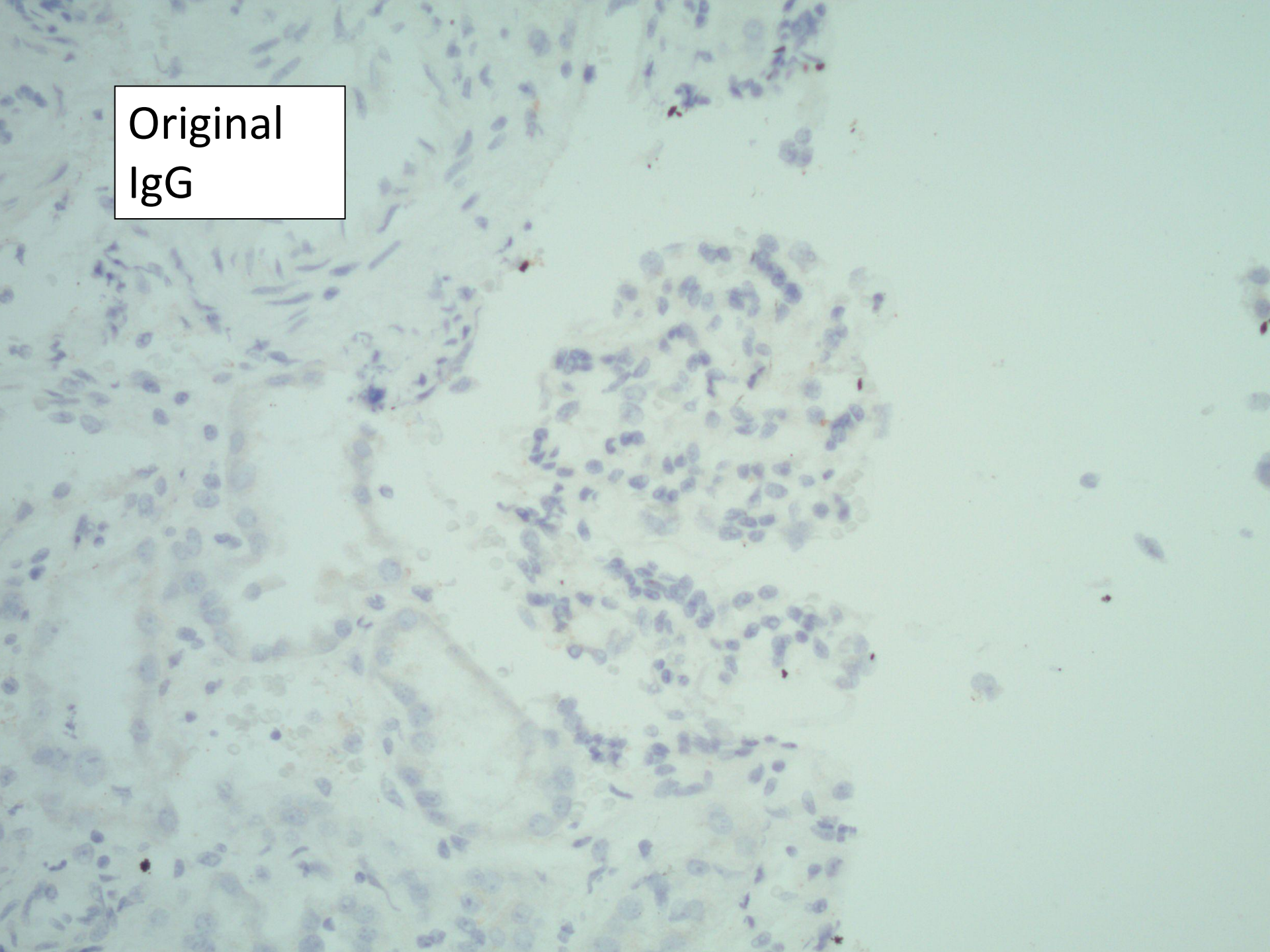


Biopsy from 1 year ago

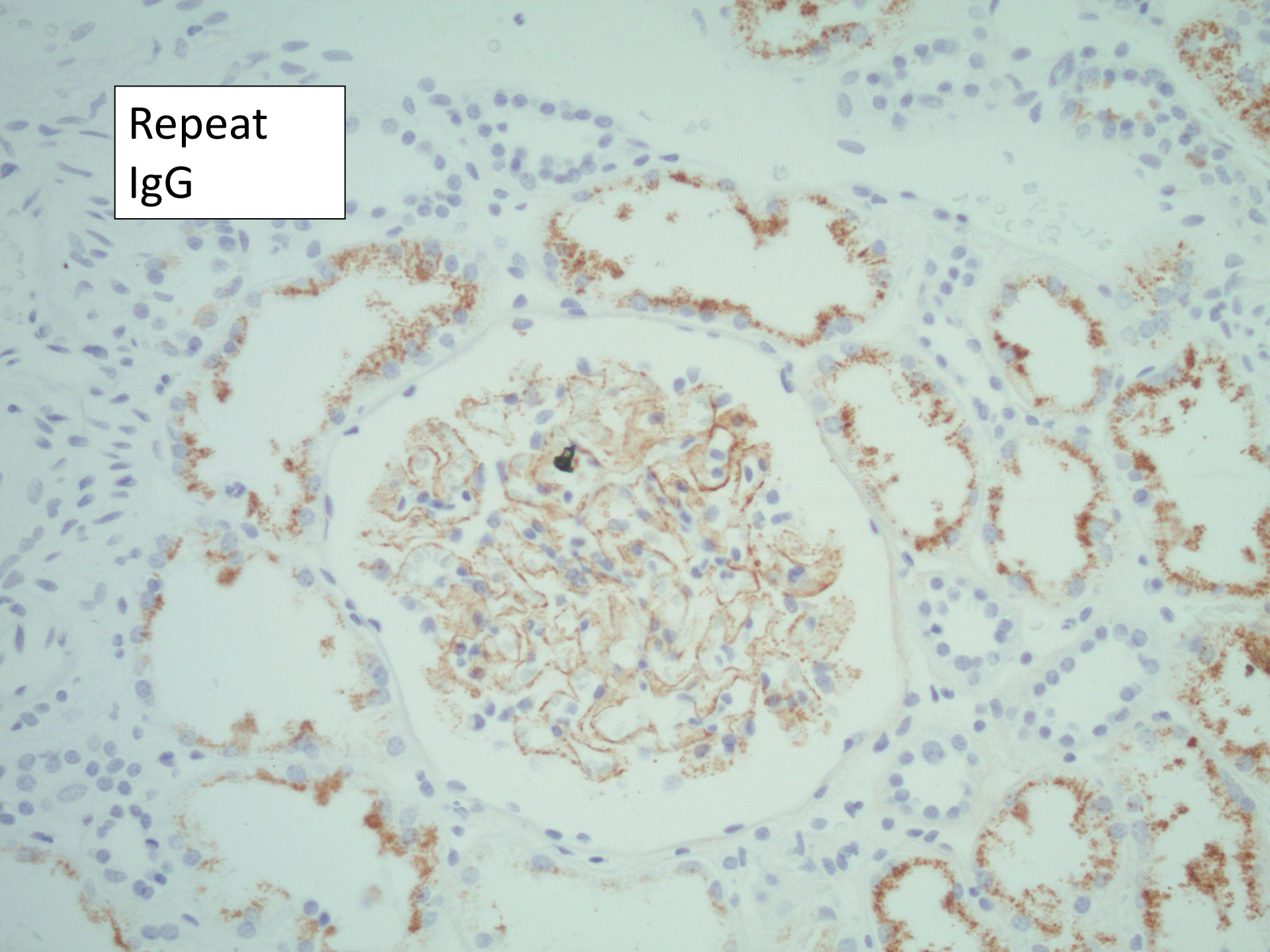




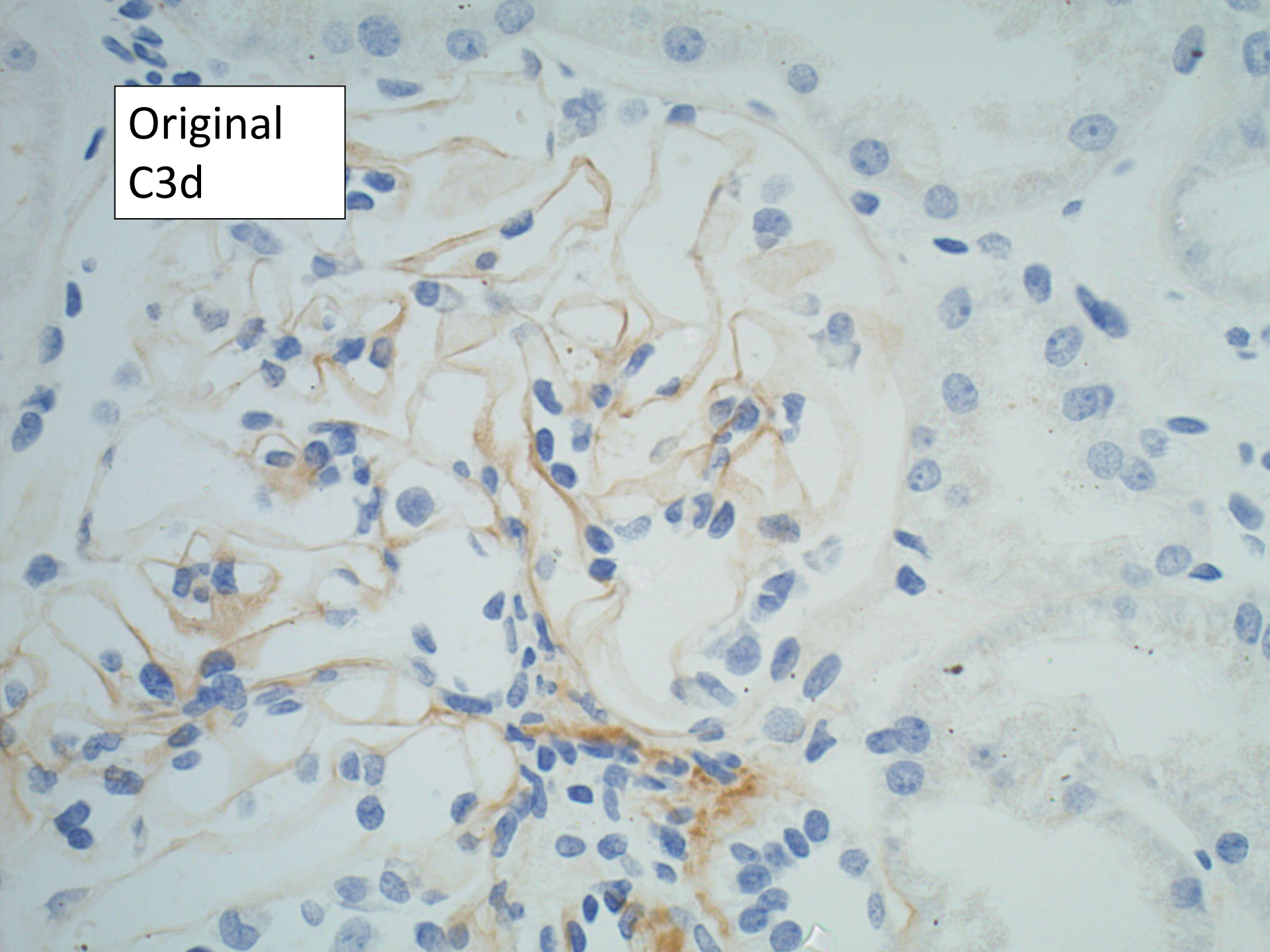
Original
IgG



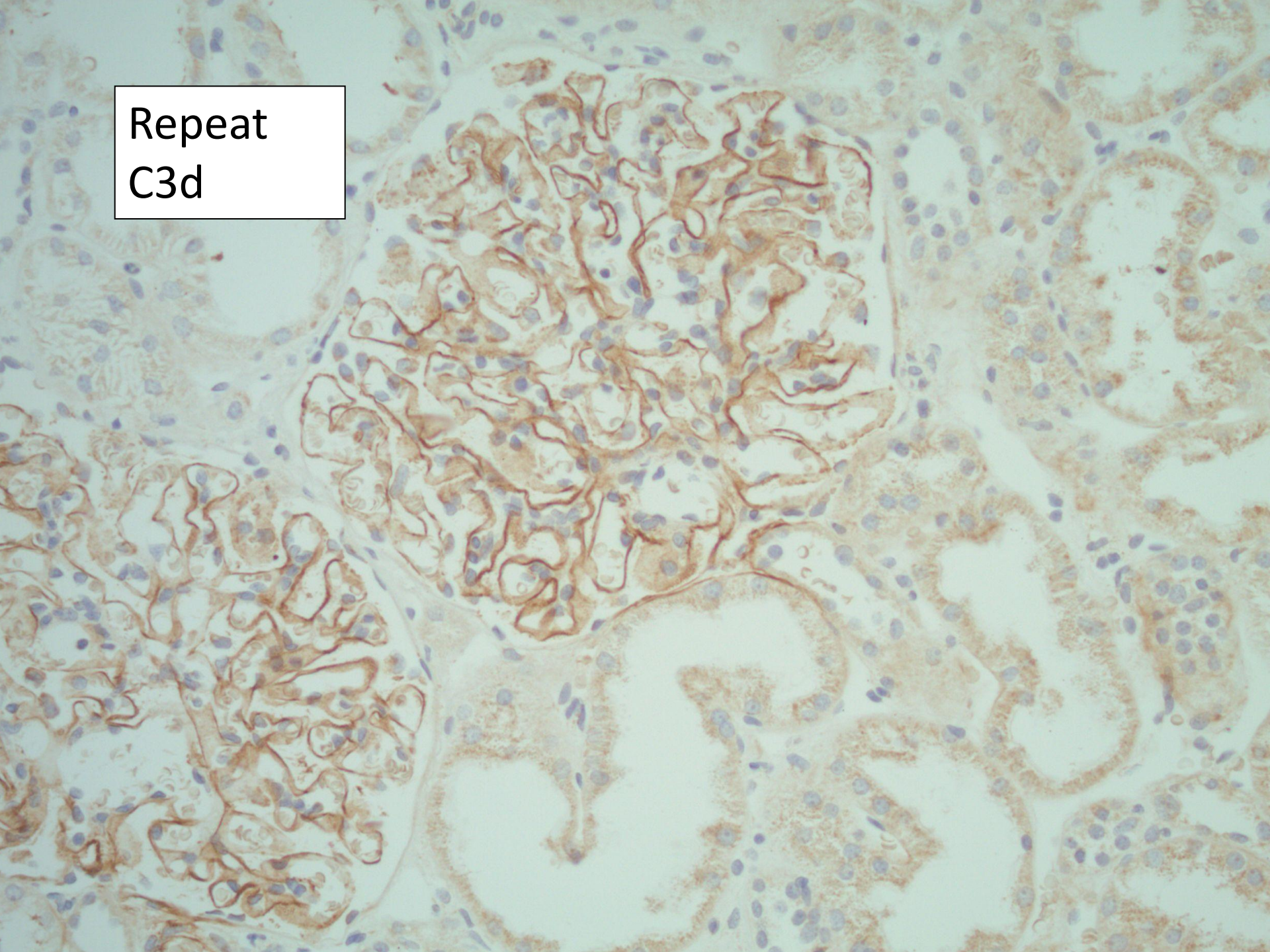
Repeat
IgG



Original
C3d



Repeat
C3d



?take home message

- **ALWAYS** do immuno and EM of all cases of apparent minimal change disease